

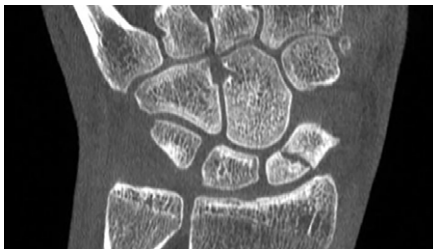

# Extremity CT Imaging for Orthopedics

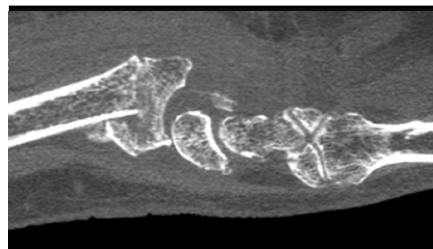
Low Dose | Comfortable Seated or Standing Position | Quick Scan Times

## Common Indications

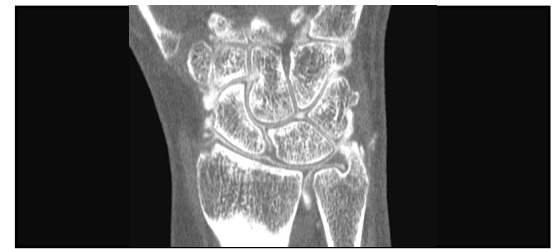### Scaphoid Fracture



### Distal Radius Fracture

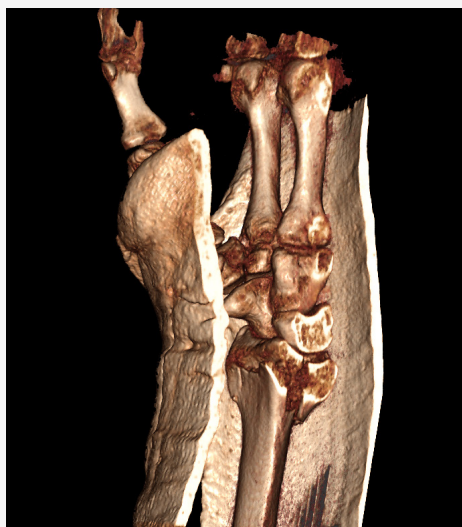

### TFCC Tear



- A feasible alternative to MDCT for the detection of extremity fractures at a reduced radiation dose.<sup>1</sup>
- Post-operatively, CBCT can diagnose scaphoid union at an early follow-up and prevents longer immobilization and interruption of activity or work.<sup>2</sup>
- Patient injected with 1cc or less of contrast, as opposed to 8-10cc required for an MRI exam.
- Patients with metal implants can obtain advanced diagnostic imaging.

## Low Dose



Radiation exposure in CBCT scans have been estimated to be approximately 10-66% less than conventional CT scanners.<sup>3</sup>

“ Considering the low dose of radiation and high image quality, CBCT could be used as a priority method of choice to assess the structure of wrist and hand bones and be done as the first step in diagnostics, replacing standard radiography. ”

A.Yu. Vasiliev, et al. Int Journal of Biomedicine

(1) Fitzpatrick, E., Sharma, V., Rojoa, D. et al. The use of cone-beam computed tomography (CBCT) in radiocarpal fractures: a diagnostic test accuracy meta-analysis. *Skeletal Radiol* 51, 923–934 (2022). <https://doi.org/10.1007/s00256-021-03883-9>  
 (2) Lucia Calisto Farracho, Berenice Moutinot, Angeliki Neroladaki, Marion Hamard, Karel Gorican, Pierre Alexandre Poletti, Jean Yves Beaulieu, Cindy Bouvet, Sana Boudabbous, Determining diagnosis of scaphoid healing: Comparison of cone beam CT and X-ray after six weeks of immobilization, *European Journal of Radiology Open*, Volume 7, 2020, 100251, ISSN 2352-0477. <https://doi.org/10.1016/j.ejro.2020.100251>  
 (3) Conti, Matthew S. MD; Ellis, Scott J. MD. Weight-bearing CT Scans in Foot and Ankle Surgery. *Journal of the American Academy of Orthopaedic Surgeons* 28(14):p e595-e603, July 15, 2020. | DOI: 10.5435/JAAOS-D-19-00700